


09/26/05 01:07 PM(QOPQAI)

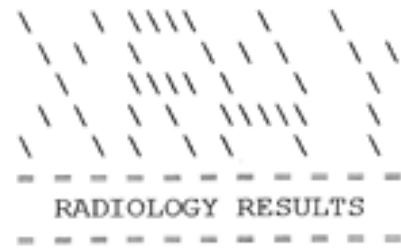

MERRINGTON, DANIEL M 28
0001474267 ADM: 09/01/05
0524480010
GRUNER, ROBERT MD EMERG

ORDER: ABD, PORTABLE 2.01
XRAY FILE: RADIOLOGIST: FLOREK

PORTABLE ABDOMEN
CLINICAL INFORMATION: GUNSHOT WOUND
RESULTS: SUPINE FRONTAL VIEW OF THE ABDOMEN OF SEPTEMBER 1, 2005
AT 1530 HOURS SHOWS NUMEROUS BUCKSHOT SCATTERED THROUGHOUT THE
ABDOMEN, MORE NUMEROUS ON THE RIGHT SIDE. NO FREE AIR IS SEEN
UNDER THE DIAPHRAGMS, NO MASS EFFECT IS SEEN.
IMPRESSION: NUMEROUS METALLIC BUCKSHOT.] PORTABLE ABDOMEN
CLINICAL INFORMATION: GUNSHOT WOUND
RESULTS: SUPINE FRONTAL VIEW OF THE ABDOMEN OF SEPTEMBER 1, 2005
AT 1530 HOURS SHOWS NUMEROUS BUCKSHOT SCATTERED THROUGHOUT THE
ABDOMEN, MORE NUMEROUS ON THE RIGHT SIDE. NO FREE AIR IS SEEN
UNDER THE DIAPHRAGMS, NO MASS EFFECT IS SEEN.
IMPRESSION: NUMEROUS METALLIC BUCKSHOT.]
LAST PAGE

09/26/05 01:07 PM(QOPQAI)



MERRINGTON, DANIEL M 28
0001474267 ADM: 09/01/05
0524480010
GRUNER, ROBERT MD EMERG

ORDER: ABD, PORTABLE 3.01
XRAY FILE:

RADIOLOGIST: FLOREK

PORTABLE ABDOMEN
CLINICAL INFORMATION: GUNSHOT WOUND
RESULTS: A SINGLE LATERAL VIEW OF THE ABDOMEN OF SEPTEMBER 1, 2005
AT 1530 HOURS SHOWS NUMEROUS SCATTERED METALLIC BUCKSHOT BOTH
ANTERIORLY AND POSTERIORLY. NORMAL ALIGNMENT OF THE LUMBAR SPINE
IS NOTED.
IMPRESSION: NUMEROUS SCATTERED METALLIC BUCKSHOT.] PORTABLE
ABDOMEN
CLINICAL INFORMATION: GUNSHOT WOUND
RESULTS: A SINGLE LATERAL VIEW OF THE ABDOMEN OF SEPTEMBER 1, 2005
AT 1530 HOURS SHOWS NUMEROUS SCATTERED METALLIC BUCKSHOT BOTH
ANTERIORLY AND POSTERIORLY. NORMAL ALIGNMENT OF THE LUMBAR SPINE
IS NOTED.
IMPRESSION: NUMEROUS SCATTERED METALLIC BUCKSHOT.]
LAST PAGE



MERRINGTON, DANIEL M 28
0001474267 ADM: 09/01/05
0524480010
GRUNER, ROBERT MD EMERG

RADIOLOGY RESULTS

ORDER: CERVICAL, SPINE PORT. 4.01
XRAY FILE:

RADIOLOGIST: FLOREK

CERVICAL SPINE:

CLINICAL INFORMATION: GUNSHOT WOUND.

RESULTS: PORTABLE FRONTAL VIEW OF THE CERVICAL SPINE OF 9/01/05,
AT 1530 HOURS, SHOWS NO BONY FRACTURE OR DISLOCATION. NUMEROUS
METALLIC BUCKSHOT ARE SEEN, AT LEAST SEVEN IN THE RIGHT NECK. THE
TRACHEA IS MIDLINE. NO MEDIASTINAL WIDENING OR SHIFT IS SEEN.

IMPRESSION: SEVEN METALLIC BUCKSHOT IN THE RIGHT NECK.] CERVICAL
SPINE:

CLINICAL INFORMATION: GUNSHOT WOUND.

RESULTS: PORTABLE FRONTAL VIEW OF THE CERVICAL SPINE OF 9/01/05,
AT 1530 HOURS, SHOWS NO BONY FRACTURE OR DISLOCATION. NUMEROUS
METALLIC BUCKSHOT ARE SEEN, AT LEAST SEVEN IN THE RIGHT NECK. THE
TRACHEA IS MIDLINE. NO MEDIASTINAL WIDENING OR SHIFT IS SEEN.

IMPRESSION: SEVEN METALLIC BUCKSHOT IN THE RIGHT NECK.]

LAST PAGE

